

LECTURE ON ELBOW JOINT

Dr Kaweri Dande

Senior Resident

Department Of Anatomy

King Georges Medical University

Disclaimer

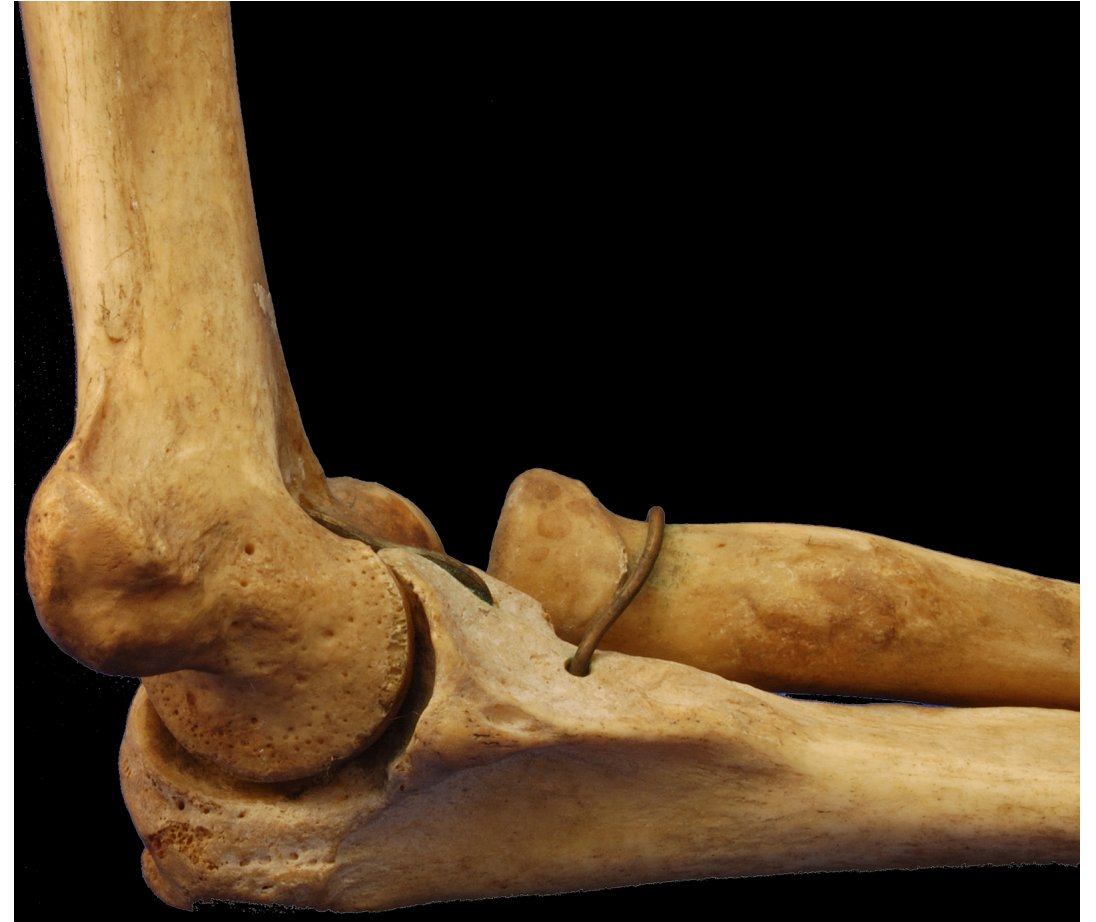- The presentation includes images which are either hand drawn or have been taken from google images or books.
- They are being used in the presentation only for educational purpose.
- The author of the presentation claims no personal ownership over images taken from books or google images.
- However, the hand drawn images are the creation of the author of the presentation

Learning Objectives

- By the end of this teaching session all the students must be able to correctly:-
- Describe the type, articular surface, capsule of elbow joint
- Describe the synovial membrane, ligaments, relations of elbow joint
- Describe the movements, vascular supply, nerve supply of elbow joint
- Describe the applied anatomy of the elbow joint

Elbow joint

- Preface
- Articular surface
- Ligaments
- Relations
- Vascular supply
- Innervation
- Movements
- Carrying angle
- Clinical anatomy



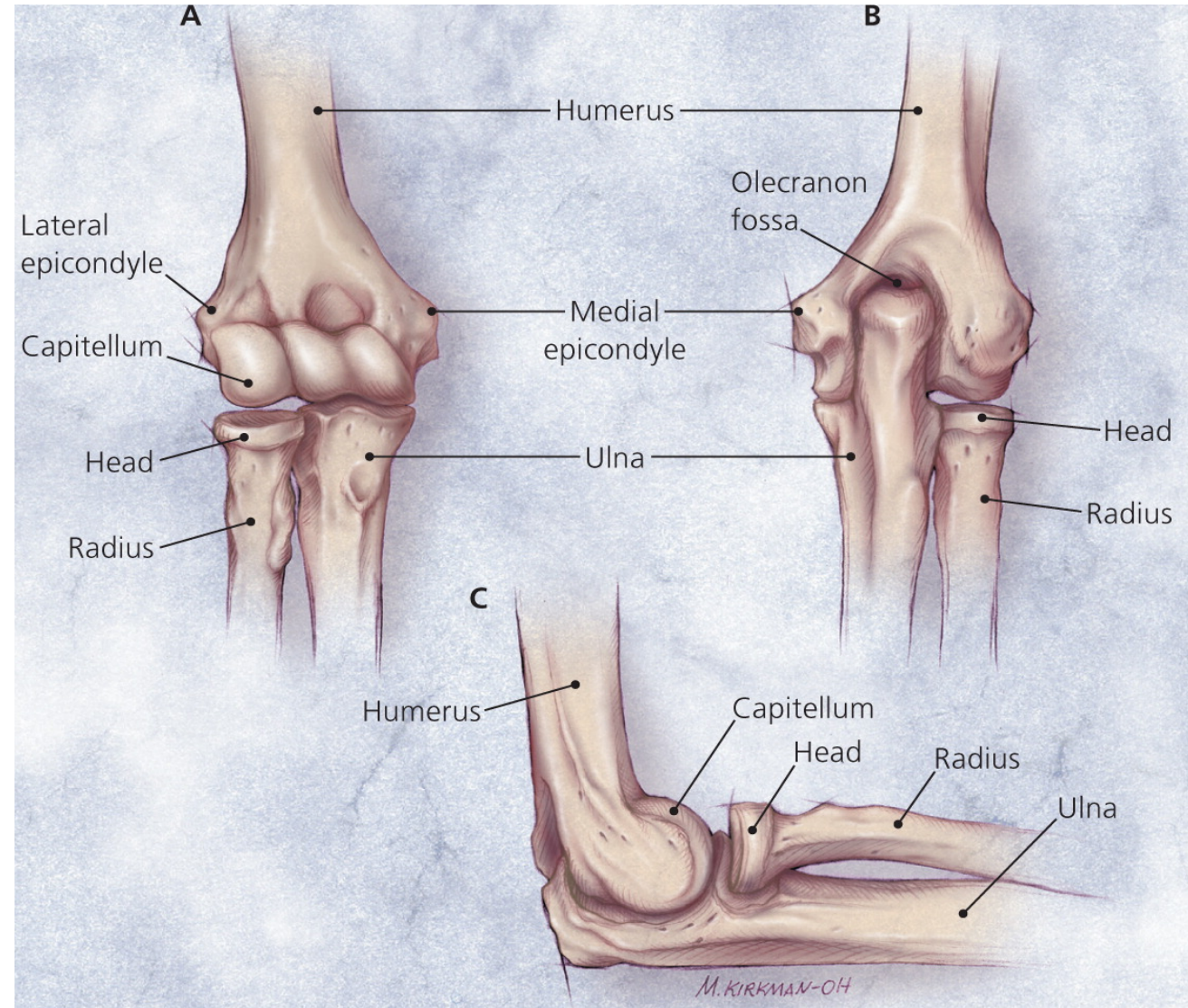
Preface

- Hinge variety of synovial joint

- *Location:* between

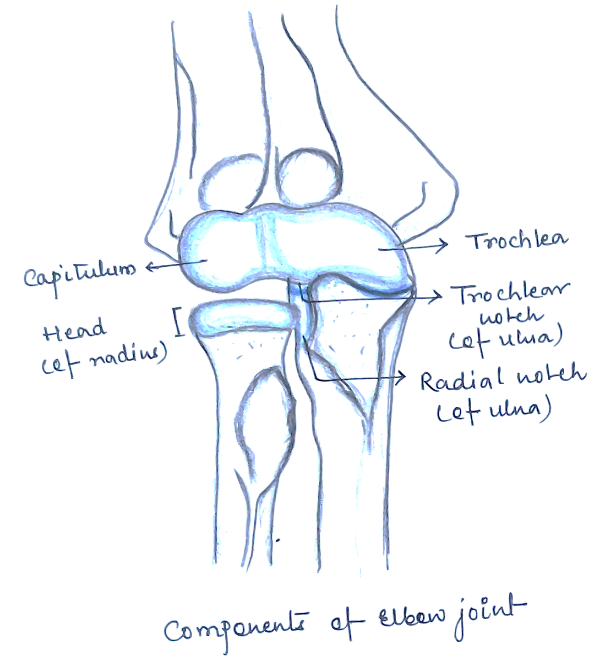
lower end of humerus

upper ends of radius & ulna



Articular surfaces

- Upper: capitulum & trochlea of humerus
- Lower : upper surface of head of radius: capitulum
trochlear notch of ulna: trochlea

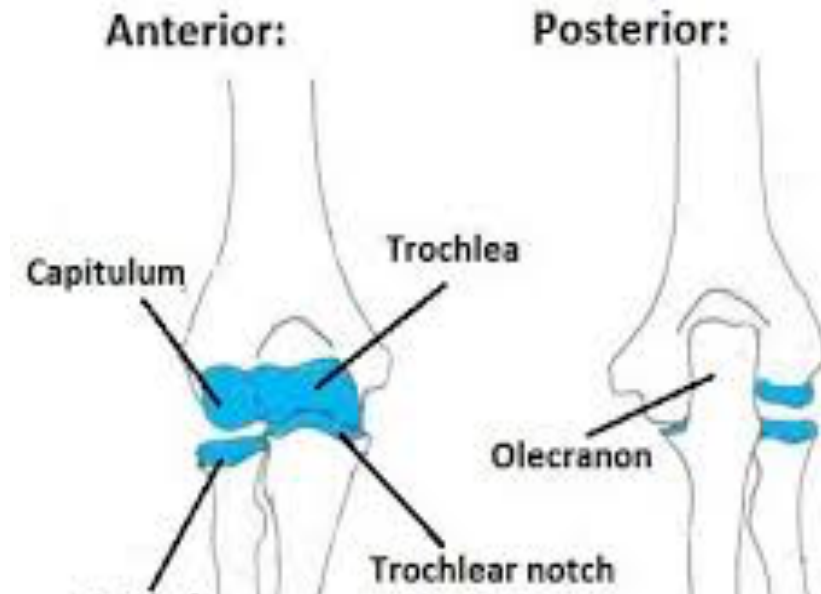


Note: continues with superior radioulnar joint

Cubital articulation

- *Cubital articulation:*

Collaboration of
Humeroradial
Humeroulnar
Superior radioulnar



ligaments

- ***Capsular ligament:***

Superiorly: lower end of humerus

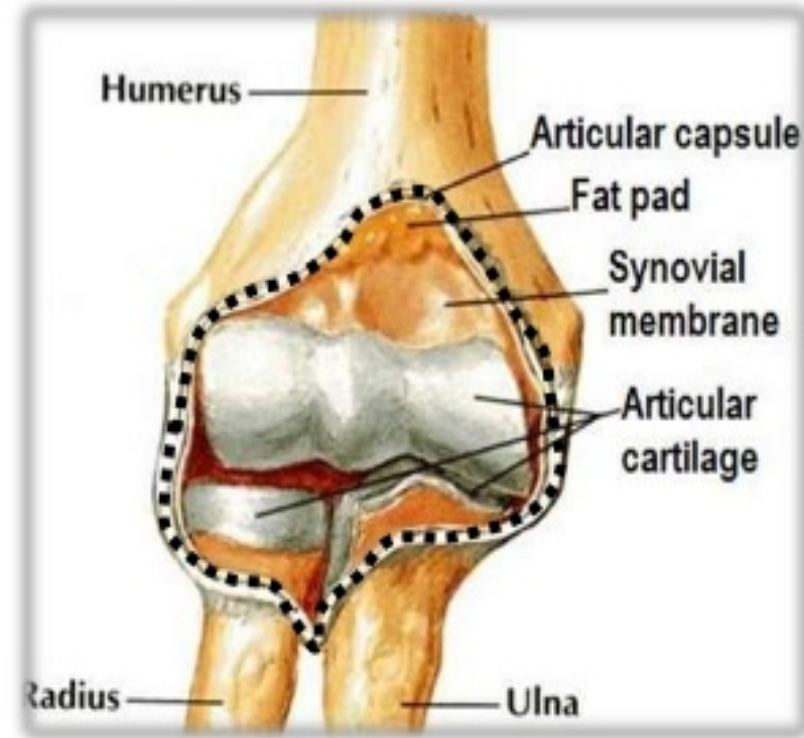
Inferomedially: trochlear notch of ulna

Inferolaterally: annular ligament of superior radioulnar

Synovial membrane lines capsule & fossae

Intracapsular:

Capitulum, trochlea, radial fossa, coronoid fossa, olecranon fossa



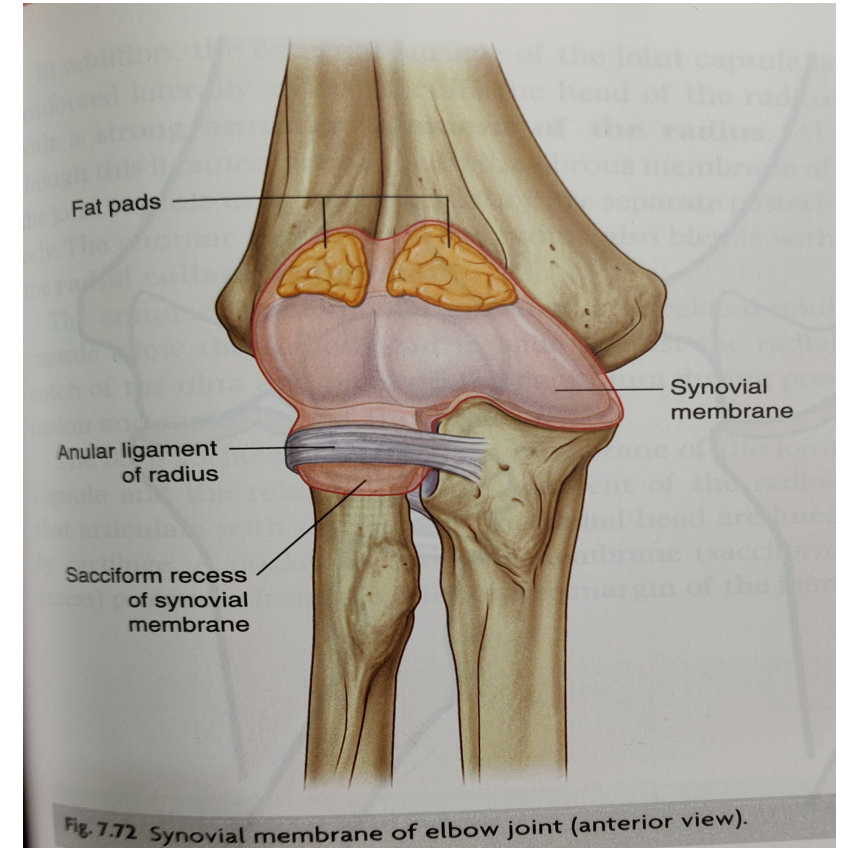
Synovial membrane lines capsule & fossae

Intracapsular:

Capitulum,
trochlea, radial fossa,
coronoid fossa, olecranon fossa

- *Thickening of capsule*

Anterior ligament & Posterior ligament



Ulnar collateral ligament

- Triangular

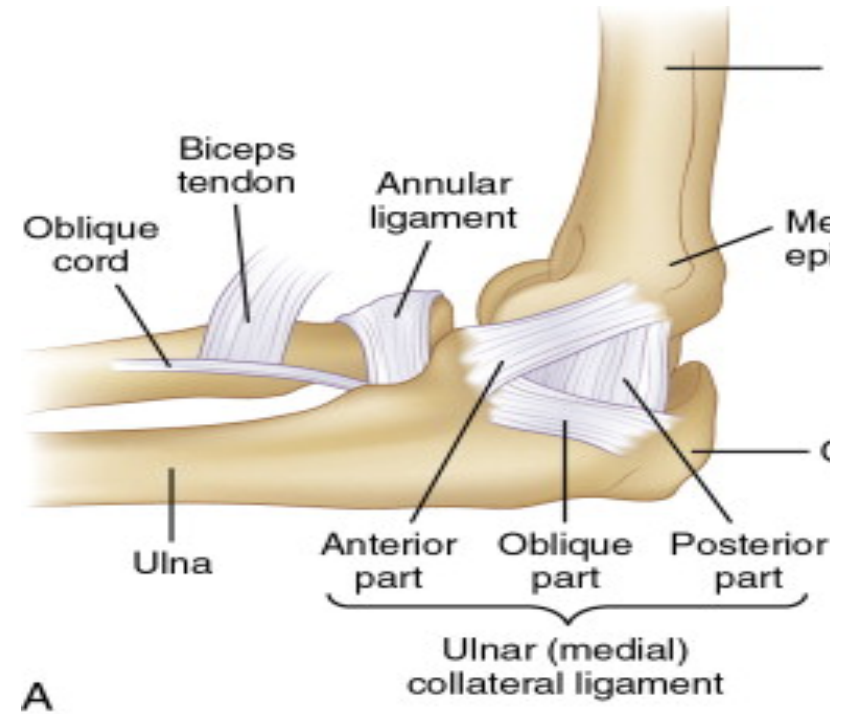
Apex: medial epicondyle of humerus

Base: ulna

Parts: Anterior band

Posterior band

Oblique band



NOTE

Crossed by ulnar nerve

Origin : flexor digitorum superficialis

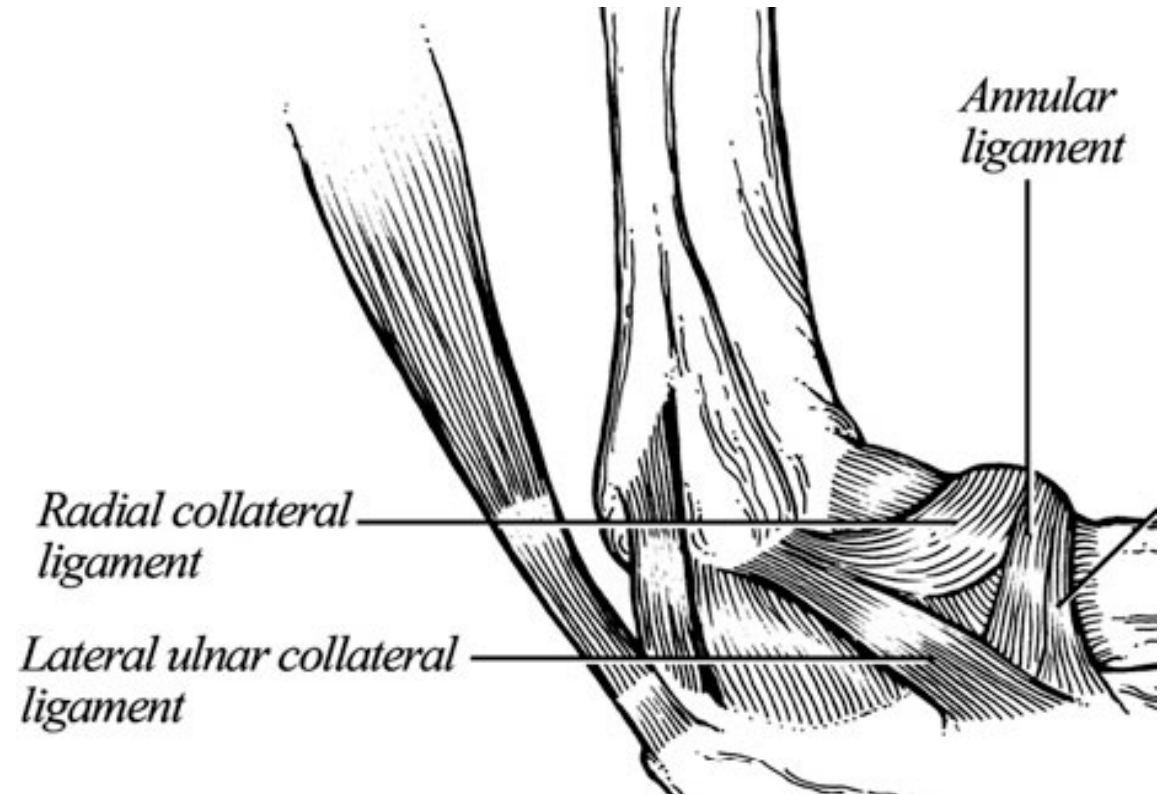
Radial collateral/ lateral ligament

- Fan shaped:
- Extension
lateral epicondyle to annular ligament

NOTE

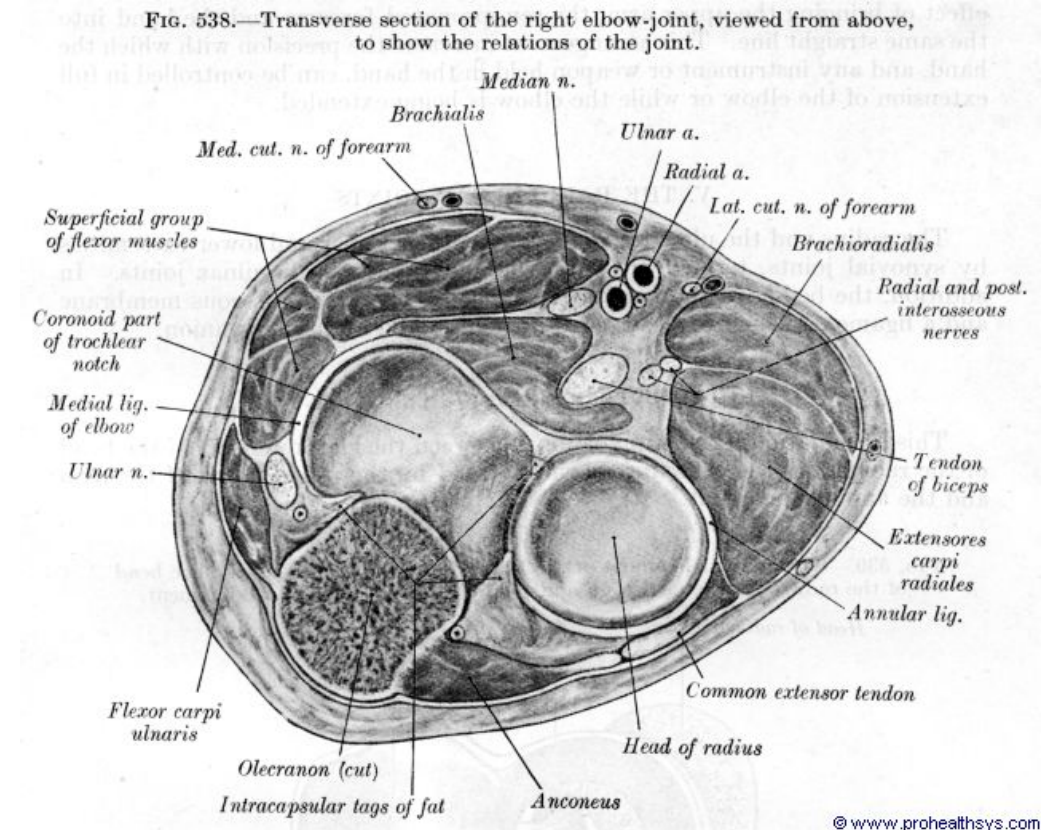
Origin: supinator

extensor carpi radialis

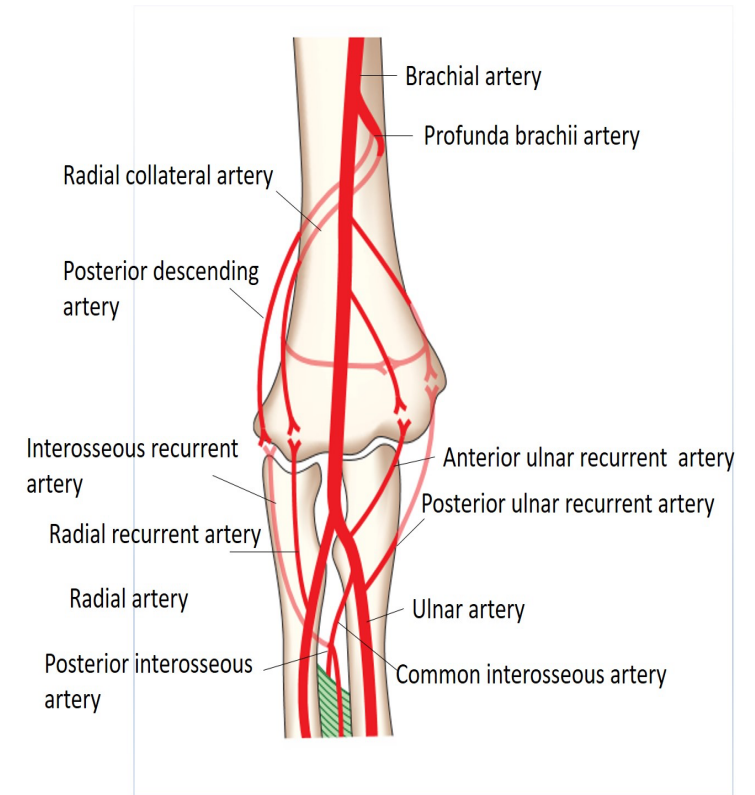


Relations

- Anteriorly: brachialis, median nerve, brachial artery, biceps tendon
- Posteriorly: triceps & anconeus
- Medially: ulnar nerve, flexor carpi ulnaris, common flexors
- Laterally: supinator, extensor carpi radialis brevis, common extensors



- ***Vascular supply:*** anastomosis around elbow joint

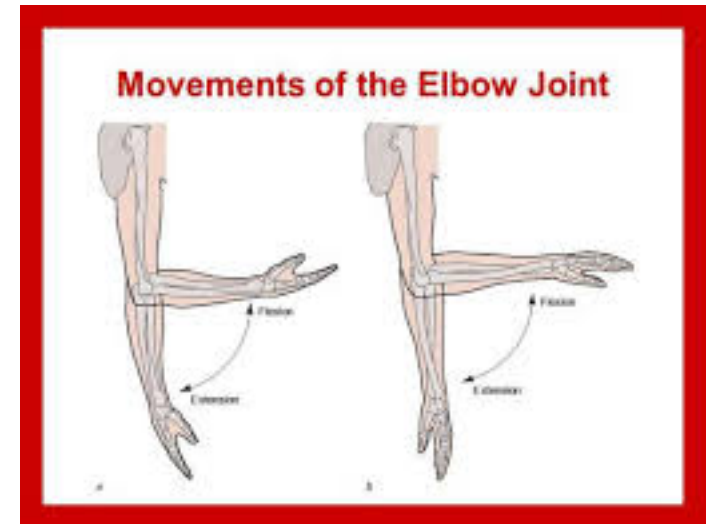


- ***Innervation:*** receives branches
ulnar, median, radial, musculocutaneous

Movements

- ***Flexion***: brachialis, biceps, brachioradialis

- ***Extension***: triceps, anconeus



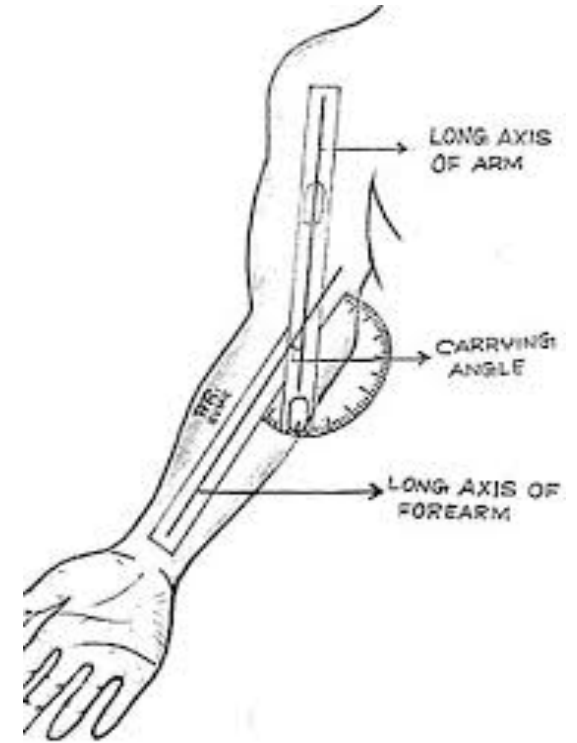
Carrying angle

- Transverse axis of elbow directed medially & downwards
- Extended forearm makes angle of 163° with arm

Factors

Medial flange of trochlea 6mm deeper

Superior articular surface of coronoid process is oblique to long axis of bone



Clinical anatomy

- Distension of elbow
- Dislocation of elbow
- Subluxation of elbow
- Tennis elbow
- Miner's (or student elbow)
- Optimum position of elbow

never
never
never
give
up

(winston churchill)

Thank you